

# Corneal Collagen Cross-linking for Terrien Marginal Degeneration

Farhad Hafezi, MD, PhD; Zisis Gatzoufas, MD, PhD;

Theo G. Seiler, MD; Theo Seiler, MD, PhD

## ABSTRACT

**PURPOSE:** To report the long-term clinical outcome of a patient diagnosed as having Terrien marginal degeneration (TMD) who was subjected to corneal collagen cross-linking (CXL) with ultraviolet-A and riboflavin in both eyes.

**METHODS:** Topographical changes were assessed by high-resolution Scheimpflug imaging and anterior segment optical coherence tomography. Eccentric epithelium-off CXL was performed in both eyes while protecting the corneal limbus. Irradiation was performed with a fluence of 5.4 J/cm<sup>2</sup>, using 3 mW/cm<sup>2</sup> for 30 minutes.

**RESULTS:** Five years of postoperative follow-up showed regression of the keratometric values, a local thickening of the corneal stroma, and bilateral improvement of corrected distance visual acuity.

**CONCLUSIONS:** CXL may arrest progression in TMD and even reverse the catabolic process in the corneal stroma. CXL might represent an alternative therapeutic approach for the management of TMD.

[J Refract Surg. 2014;30(7):498-500.]

Terrien marginal degeneration (TMD) is a rare, bilateral, progressive corneal melting disease, usually occurring in middle to late age.<sup>1</sup> It is characterized by progressive peripheral stromal thinning typically observed in the superior quadrants as fine yellow-white punctate stromal opacities that progressively involve the entire circumference of the peripheral cornea with neovascularization, scarring, and lipid deposits at the edge.<sup>1</sup> Atypical manifestations of TMD include an inflammatory variant with a presence of pseudo-pterygium and even spontaneous corneal perforation.<sup>2</sup>

From the Department of Ophthalmology, Geneva University Hospitals, Geneva, Switzerland (FH, ZG); and the Institute for Refractive and Ophthalmic Surgery, Zurich, Switzerland (TGS, TS).

Submitted: April 10, 2014; Accepted: April 17, 2014; Posted online: June 3, 2014

The authors have no financial or proprietary interest in the materials presented herein.

Correspondence: Farhad Hafezi, MD, PhD, Department of Ophthalmology, Geneva University Hospitals, Rue Alcide Jentzer 22, Geneva 14, 1211 Switzerland. E-mail: farhad@hafezi.ch

doi:10.3928/1081597X-20140527-02

Management of TMD remains a major therapeutic challenge: lamellar keratoplasty techniques that have been proposed for the treatment of sight-threatening complications, such as corneal perforation, are complicated and have shown only moderate success.<sup>3,4</sup>

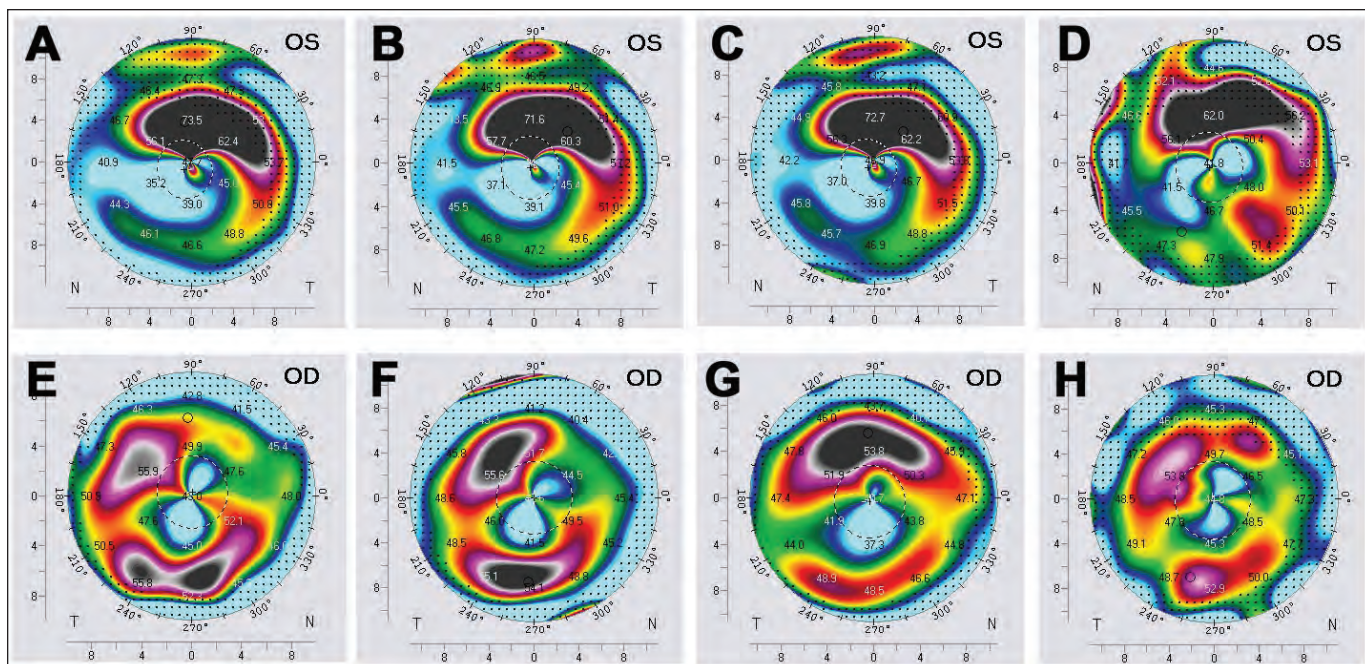
Corneal collagen cross-linking (CXL) is an effective and safe method for the treatment of corneal ectatic diseases such as keratoconus and iatrogenic corneal ectasia.<sup>5,6</sup> CXL has also been successfully used in non-infectious corneal melting.<sup>7</sup> Here, the proposed mechanism of action is an increased resistance of the corneal stroma to enzymatic digestion.<sup>8,9</sup>

In this report, we highlight the case of a patient diagnosed as having TMD who was successfully treated with CXL, which resulted in arrest of TMD progression, partial reversal of the melting–thinning process, and improvement of visual acuity.

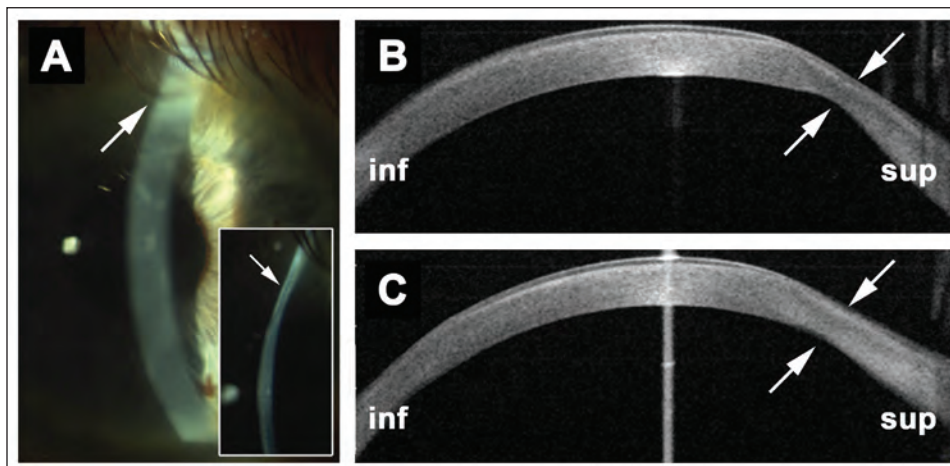
## CASE REPORT

A 47-year-old man presented with reduced visual acuity and increasing astigmatism and was diagnosed as having TMD in 2007. In January 2008, he was referred to our clinic in Zurich, Switzerland. Slit-lamp examination and corneal topography by Scheimpflug imaging confirmed the presence of bilateral TMD in the superior peripheral cornea. The average keratometry value measured within the central 3 mm was 44.4 diopters (D). The maximal keratometry value measured was 53.0 D in the right eye, whereas the mean and maximal keratometry values were 50.5 and 81.5 D in the left eye at presentation, respectively. The thinnest corneal points for the right and left eyes were 464 and 414  $\mu$ m, respectively. Corneal thickness was determined optically using a Scheimpflug imaging system (Pentacam; Oculus Optikgeräte, Wetzlar, Germany) preoperatively and for all follow-up measurements. Corrected distance visual acuity (CDVA) with contact lenses was 5/10 (Snellen 20/40) in the right eye and 3/10 (Snellen 20/63) in the left eye. After a thorough discussion with the patient, we decided to perform CXL on the left eye.

In May 2008, an eccentric epithelium-off CXL procedure was performed on the left eye by decentering the irradiation zone to cover the area of active melting and thinning in the superior periphery of the cornea. The remainder of the procedure was performed according to the standard Dresden protocol (fluence: 5.4 J/cm<sup>2</sup>, settings: 3 mW/cm<sup>2</sup> for 30 minutes), with a sponge protecting the corneal limbus. Postoperatively, ofloxacin ointment was applied every 2 hours during the day and before bedtime until complete closure of the epithelium, followed by fluorometholone eye drops twice daily for 4 weeks.



**Figure 1.** Corneal topography by Scheimpflug imaging (Pentacam HR; Oculus Optikgeräte, Wetzlar, Germany) of the right (OD) and left (OS) eyes in a patient diagnosed as having Terrien marginal degeneration. When compared to the (A) preoperative state, a progressive decrease of the keratometric readings at (B) 1, (C) 3, and (D) 5 years after corneal collagen cross-linking was observed in the left eye. Similarly, keratometric readings improved in the right eye at (F) 1, (G) 2, and (H) 3 years after cross-linking when compared to (E) preoperative maximal keratometry values.



**Figure 2.** (A; arrows and inset) Slit-lamp images of the superior peripheral thinning in the right eye. Prior to corneal collagen cross-linking, minimal stromal thickness over the ectatic area of the right peripheral superior cornea was (B, arrows) 380  $\mu$ m and increased to (C, arrows) 424  $\mu$ m at 1 year postoperatively. Inf = inferior; sup = superior

One year after CXL, mean and maximal keratometry values decreased to 49.0 and 76.6 D, respectively, and continued to decrease during the following years: the mean keratometry value was 47.7 D and the maximal keratometry value was 72.7 D at 3 years postoperatively. The mean keratometry value remained stable at 47.6 D, whereas the maximal keratometry value regressed to 67.7 D at 5 years postoperatively (**Figures 1A-1D**). CDVA was 4/10 (Snellen 20/50) at 1 year and 6/10 at 3 and 5 years postoperatively. The patient was able to wear semi-rigid, gas permeable contact lenses again starting at 1 year after CXL. The thinnest corneal point increased to 450  $\mu$ m, as measured optically by Scheimpflug imaging in 2013.

In August 2011, the patient also showed significant progression of the right eye, with a mean keratometry value of 47.4 D, maximal keratometry value of 59.0 D, CDVA with contact lenses of 3/10 (Snellen 20/63), and minimal corneal thickness of 380  $\mu$ m. In light of the successful CXL treatment of the left eye, we decided to proceed with CXL of the right eye. The mean and maximal keratometry values decreased to 46.7 and 56.5 D, respectively, by 1 year after CXL. Two years postoperatively, mean and maximal keratometry values were 45.7 and 55.4 D, respectively (**Figures 1E-1H**). CDVA increased to 4/10 (Snellen 20/50) at 2 years after CXL. The thinnest corneal point increased from 380  $\mu$ m

preoperatively to 424  $\mu\text{m}$  at 1 year postoperatively (**Figure 2**). No complications have occurred to date and the patient is satisfied with the visual outcome and the fact that he now tolerates wearing rigid contact lenses for approximately 9 hours per day in both eyes.

## DISCUSSION

Our patient presented with bilateral progressive TMD and was treated with an eccentric epithelium-off CXL using the parameters of the original Dresden protocol. Long-term follow-up showed that keratometric values decreased significantly, resulting in marked improvement of CDVA.

However, the most striking finding was an increase of corneal thickness over the melting ectatic area. One might speculate that CXL induced a reversal of corneal thinning. This phenomenon could be explained by the fact that CXL causes a significant increase in the resistance of corneal stroma to enzymatic digestion.<sup>8,9</sup> Corneal homeostasis of the stromal extracellular matrix is determined by a delicate balance between collagen synthesis via corneal keratocytes and collagen catalysis, mediated by digestive enzymes such as matrix metalloproteinases.<sup>10</sup> Corneal cross-linked collagen types I and IV are resistant to cleavage by matrix metalloproteinases (MMP-1, MMP-2, MMP-9, and MMP-13), whereas non-cross-linked collagens I and IV and natively glycosylated, small leucine-rich proteoglycans are susceptible to degradation by matrix metalloproteinases.<sup>10</sup> An increased resistance of the corneal stroma to enzymatic digestion might downregulate the catalytic activity with a subsequent net increase in collagen production and a resulting augmentation of corneal stroma.

We did not measure endothelial cell density in both eyes treated because this would not have had a therapeutic consequence; corneal grafting is usually performed in cases of advanced progressive TMD with local thinning. CXL represents an attempt to avoid keratoplasty and potential local damage to the endothelial cells would be acceptable in light of preservation of the patient's cornea. Postoperatively, we did not observe endothelial decompensation in either eye.

To date, there is no accepted invasive therapeutic approach for the management of TMD. Lamellar keratoplasty (crescent-shaped or ring-shaped) has been proposed, but wide clinical acceptance is still pending.<sup>3,4</sup> Regarding penetrating keratoplasty, we expect only a

minimal success rate because of the proximity to the limbus and its potential for rejection.

Our data suggest that CXL might arrest and partially reverse progressive peripheral corneal thinning in TMD and may contribute to the improvement of visual acuity. If further data validate the efficacy and safety of CXL in the treatment of TMD, then it might become a treatment option and may even be used prophylactically as soon as the diagnosis of TMD is confirmed.

## AUTHOR CONTRIBUTIONS

*Study concept and design (FH, TS); data collection (TGS); analysis and interpretation of data (FH, ZG); writing the manuscript (FH, ZG); critical revision of the manuscript (TGS, TS); administrative, technical, or material support (TGS, TS)*

## REFERENCES

1. Beauchamp GR. Terrien's marginal corneal degeneration. *J Pediatr Ophthalmol Strabismus*. 1982;19:97-99.
2. Srinivasan S, Murphy CC, Fisher AC, Freeman LB, Kaye SB. Terrien marginal degeneration presenting with spontaneous corneal perforation. *Cornea*. 2006;25:977-980.
3. Bi YL, Bock F, Zhou Q, Cursiefen C. Central corneal epithelium self-healing after ring-shaped glycerin-cryopreserved lamellar keratoplasty in Terrien marginal degeneration. *Int J Ophthalmol*. 2013;6:251-252.
4. Huang T, Wang Y, Ji J, Gao N, Chen J. Evaluation of different types of lamellar keratoplasty for treatment of peripheral corneal perforation. *Graefes Arch Clin Exp Ophthalmol*. 2008;246:1123-1131.
5. Raiskup-Wolf F, Hoyer A, Spoerl E, Pillunat LE. Collagen cross-linking with riboflavin and ultraviolet-A light in keratoconus: long-term results. *J Cataract Refract Surg*. 2008;34:796-801.
6. Richoz O, Mavrakanas N, Pajic B, Hafezi F. Corneal collagen cross-linking for ectasia after LASIK and photorefractive keratectomy: long-term results. *Ophthalmology*. 2013;120:1354-1359.
7. Schnitzler E, Spörl E, Seiler T. Irradiation of cornea with ultraviolet light and riboflavin administration as a new treatment for erosive corneal processes, preliminary results in four patients [article in German]. *Klin Monbl Augenheilkd*. 2000;217:190-193.
8. Hayes S, Kamma-Lorger CS, Boote C, et al. The effect of riboflavin/UVA collagen cross-linking therapy on the structure and hydrodynamic behaviour of the ungulate and rabbit corneal stroma. *PLoS One*. 2013;8:e52860.
9. Spoerl E, Wollensak G, Seiler T. Increased resistance of cross-linked cornea against enzymatic digestion. *Curr Eye Res*. 2004;29:35-40.
10. Zhang Y, Mao X, Schwend T, Littlechild S, Conrad GW. Resistance of corneal RFUVA-cross-linked collagens and small leucine-rich proteoglycans to degradation by matrix metalloproteinases. *Invest Ophthalmol Vis Sci*. 2013;54:1014-1025.